Extracts from

FORENSIC MEDICINE

A GUIDE TO PRINCIPLES

I. Gordon & H.A. Shapiro

FORENSIC MEDICINE
A GUIDE TO PRINCIPLES

I. GORDON, M.B., Ch.B., F.R.S.S.Af.
Professor of Forensic Medicine, University of Natal, and
Chief Government Pathologist, Durban.
Dean, Faculty of Medicine, University of Natal, 1955-1971.

H.A. SHAPIRO, Ph.D., M.B., Ch.B., F.R.S.S.Af.
Professor of Forensic Medicine, University of South Africa.
Visiting Professor of Forensic Medicine, University of Natal.
Editor-in-Chief, *Forensic Science*.
Honorary Consulting Pathologist, National Research Institute for
Occupational Diseases, Johannesburg.
Former Government Pathologist, Cape Town.

CHURCHILL LIVINGSTONE
Edinburgh London and New York 1975

CHURCHILL LIVINGSTONE
Medical Division of Longman Group Limited

Distributed in the United States of America by
Longman Inc., New York and by associated
companies, branches and representatives
throughout the world.

First published 1975

ISBN 0 443 01215 6

Printed in Great Britain

Soothsayer. In nature's infinite book of secrecy
A little I can read.

Anthony and Cleopatra, Act I, Scene ii.

PREFACE

In this work all reference to legal systems has been eliminated because the systems vary so markedly in different jurisdictions and properly fall within the scope of the lawyer.

We have tried to reduce the vast field of Forensic Medicine to manageable proportions by emphasizing the underlying principles. A scientific evaluation of this discipline must discard the medico-legal mythology that still pervades much forensic thinking, writing and practice. Its scientific standpoint is the only one acceptable if the forensic expert is to assist our Courts in the administration of justice.

Deaths of medico-legal importance are classified so as to eliminate the confusion created by a failure to distinguish between clinical and pathological signs. Because this classification is based on the general principles of physiology, it becomes related coherently to current scientific knowledge. The Tardieu-dominated and misleading approach to the problems of asphyxia is discarded and replaced by a statement of the non-specific (general) and the specific (particular) signs resulting from anoxia, however initiated. Asphyxia is not a pathological entity which can be recognized postmortem and guidelines are provided for an objective assessment of the autopsy signs in the so-called asphyxias as well as the fairly limited inferences which may be drawn from these observations.

We regard Forensic Toxicology as a non-subject because the symptoms and signs of poisoning cannot be divorced from what is a problem in clinical medicine. The autopsy findings, in their correct perspective, are only one of the special investigations which must be considered in the differential diagnosis in order to reach a conclusion.

We have excluded such topics as Identity, Forensic Odontology, the investigation of aircraft accidents, Forensic Psychiatry, advanced laboratory techniques and the effects of ionizing radiations because, in practice, the expertise required involves the assistance of specialists in such fields as anatomy, anthropology, dentistry, psychiatry, chemistry, serology, etc. These highly specialized services are called on by the Forensic Pathologist as and when the need arises.

Durban, 1975

I.G.
H.A.S.

ACKNOWLEDGMENTS

We are indebted to:

Dr. J. J. F. Taljaard, for his assistance with the reading of proofs and the preparation of the Index;

Dr. H. S. Baar, Pathologist to the Children's Hospital, Birmingham, and the Editor of the *British Medical Bulletin,* for permission to reproduce Fig. 14.7;

Mr. G. F. Rowbotham and Churchill Livingstone, for permission to reproduce Figs. 12.1, 12.2, 12.4, 12.5, 12.7 to 12.10, 12.13, 12.15, 12.17, 12.19, and 12.21, which have been taken from the Second Edition of Rowbotham's work on *Acute Injuries of the Head,* published by E. & S. Livingstone Ltd.;

Pofessor M. R. Drennan, for permission to use Fig. 14.4 taken from his work, *A Short Course on Human Embryology,* published by the Mercantile Press, Cape Town;

Dr. A. H. S. Holbourn and the *Lancet,* for permission to reproduce Fig. 12.11;

Sir James Learmonth, for permission to use Fig. 12.28 and 12.29;

Dr. E. S. Gurdjian and the *Journal of Neurosurgery,* for the use of Figs. 12.6A to 12.6D;

Dr. J. Caffey and the *American Journal of Roentgenology, Radium Therapy and Nuclear Medicine,* for the use of Fig. 14.14;

Dr. C. Kaplan, for the use of Figs. 13.11 and 13.12;

Professor R. H. Goetz, for the photomicrograph shown in Fig. 14.6;

Mr. H. E. Straker, for the illustrations shown in Figs. 13.4 to 13.6;

Mr. J. Perlman, for preparing the illustrations shown in Figs. 10.2, 13.3 and 14.1;

The Oxford University Press, for the use of Fig. 12.27, taken from *'A Manual of Surgery',* by Thomson, Miles and Wilkie;

The Centrale Drukkerij, Utrecht, for permission to reproduce Fig. 1.4;

The British Medical Journal, for the use of Figs. 12.26 and 14.3;

The South African Medical Journal, for the use of Figs. 2.1A to 2.1C, 4.6 to 4.8, 13.9A and 13.9B;

Clinical Proceedings, for the use of Figs. 6.2, 10.2, 14.8 to 14.11;

The Journal of Forensic Medicine, for the use of Figs. 1.1, 1.2, 1.5, 3.2A to 3.2D, 4.5A to 4.5C, 4.19 and 4.20, 10.4 to 10.9;

The Commissioner of the South African Police, for permission to reproduce the police photographs taken in connection with our cases;

(Acknowledgments continued overleaf)

(Acknowledgments continued)

Mr. C. R. Stuart, Head of and members of the Department of Medical Illustration of the University of Natal, as well as the Departments of Photography of the University of the Witwatersrand and of the National Research Institute for Occupational Diseases, for providing many of the photographs and photomicrographs.

Miss C. B. Maguire, Medical Librarian of the Faculty of Medicine of the University of Natal, for her considerable assistance.

Mrs. B. M. Emmerich, for her superb secretarial work in the preparation of the manuscript.

Chapter 15 on the 'Medico-Legal Aspects of Acute Alcoholic Intoxication' is based largely on a contribution by one of us (H.A.S.) to *South African Motor Law* by W. E. Cooper and B. R. Bamford published by Juta & Co. Ltd., Cape Town and Johannesburg, 1965.

Durban,
1975

I.G.
H.A.S.

CONTENTS

4. Deaths Usually Initiated by Hypoxic Hypoxia or Anoxic Anoxia

BREATHING IN A VITIATED ATMOSPHERE

Death from hypoxic hypoxia or anoxic anoxia may result from breathing in a vitiated atmosphere. A vitiated atmosphere is deficient in oxygen. This deficiency may be caused by a displacement of oxygen from the atmosphere by inert gases or by gases generated in the atmosphere.

Among the commoner gases found in vitiated atmospheres are carbon dioxide, carbon monoxide, methane, sulphuretted in hydrogen and sulphur dioxide. A vitiated atmosphere usually contains more than one inert or toxic gas, e.g. 'sewer gas' contains carbon dioxide, sulphuretted hydrogen and methane.

Carbon dioxide is exhaled during respiration, and relatively high concentrations of this gas may accumulate in crowded poorly-ventilated places. In such circumstances persons may suffer from hypoxic or anoxic symptoms such as headache or drowsiness as the carbon dioxide displaces oxygen from the atmosphere, but it is exceptional for death to occur under these conditions.

Carbon dioxide, sulphur dioxide and carbon monoxide may be generated during the combustion of organic matter, e.g. after a mine explosion, and death is usually due to a combination of hypoxic or anoxic effects. The carbon dioxide displaces oxygen from the atmosphere; the sulphur dioxide, because of its strong reducing action, prevents haemoglobin from taking up oxygen, and the carbon monoxide displaces oxygen from its combination with the haemoglobin of the blood (p. 107).

Fatal toxic gas poisoning during fires is dealt with on page 115.

Carbon dioxide, methane and sulphuretted hydrogen are produced during the fermentation of organic matter, e.g. in sewers, deep wells, cellars, vats and silos. Death from exposure to a vitiated atmosphere in a sewer, deep well, etc., is usually due to the combined effects of several gases. Methane acts in the same manner as carbon dioxide by displacing oxygen from the atmosphere. Sulphuretted hydrogen is a strong reducing agent and although it does not combine with haemoglobin during life, it prevents the haemoglobin from taking up oxygen. After death sulphuretted hydrogen reacts with the methaemoglobin in the blood to form the compound sulphmethaemoglobin.

AUTOPSY FINDINGS

Apart from the demonstration of carboxyhaemoglobin, sulphmethaemoglobin*

* The demonstration of sulphmethaemoglobin is not diagnostic of poisoning by sulphuretted hydrogen as the compound can be produced in the blood during putrefaction.

or acid haematin in the blood in deaths from exposure to carbon monoxide, sulphuretted hydrogen or sulphur dioxide respectively, no special pathological changes are found at autopsy in deaths from breathing in vitiated atmospheres.

In all cases non-specific general pathological changes are found (Chapter 3). The intensity of the visceral congestive changes is usually well marked.

SUFFOCATION

Suffocation is an obstruction to the passage of air into the respiratory tract caused by a closing of the external respiratory orifices.

Suffocation includes the conditions of smothering and overlaying.

OCCURRENCE

Accidental. Many infants who appear to be in good health are found dead in their cribs, cots or perambulators. Such deaths are sometimes ascribed to 'accidental mechanical suffocation' when it can be shown that the infant has turned into a prone position, and has apparently buried its face in a pillow or blankets. Werne and Garrow[1] investigated the deaths of 167 infants belonging to the group which is ordinarily certified as being due to 'accidental mechanical suffocation'. In 124 of the 167 cases, the cause of death could not be determined by naked-eye examination of the viscera and tissues, but complete histological studies revealed visceral lesions. Acute inflammatory changes of the respiratory tract were observed in most of these cases.

It has been shown in Chapter 3 that there is no means of differentiating so-called asphyxial deaths from other forms of death on the basis of general pathological changes such as visceral congestion and petechial haemorrhages. For this reason an opinion that death has resulted from 'accidental mechanical suffocation' should only be given after detailed naked-eye and histological examination of the tissues have excluded any other cause of death.

Accidental suffocation of an infant by overlaying may occur in cases where the infant has to share the bed of its parent or parents.

Suicidal. This type of suffocation is uncommon. In a case reported by Turner,[2] a senior wireless operator on a merchant ship was found trussed up in his cabin with an oilskin sheet tied over his head (Fig. 4.1A). When the sheet was removed, a strap, which acted as a ligature, was found around his neck, and his arms were pinioned to his sides. His right hand was tied behind his back and a strap, which was termed the 'key strap' for convenience, was found grasped in his left hand (Figs. 4.1B and 4.1C). The photographs show how the 'key strap' passed through the loop of another strap. It was found that when the 'key strap' was pulled, all the other straps were tightened and at the same time the oilskin became firmly bound to the body. The cause of death was given as suffocation and strangulation. The inquest proceedings suggested that the deceased had

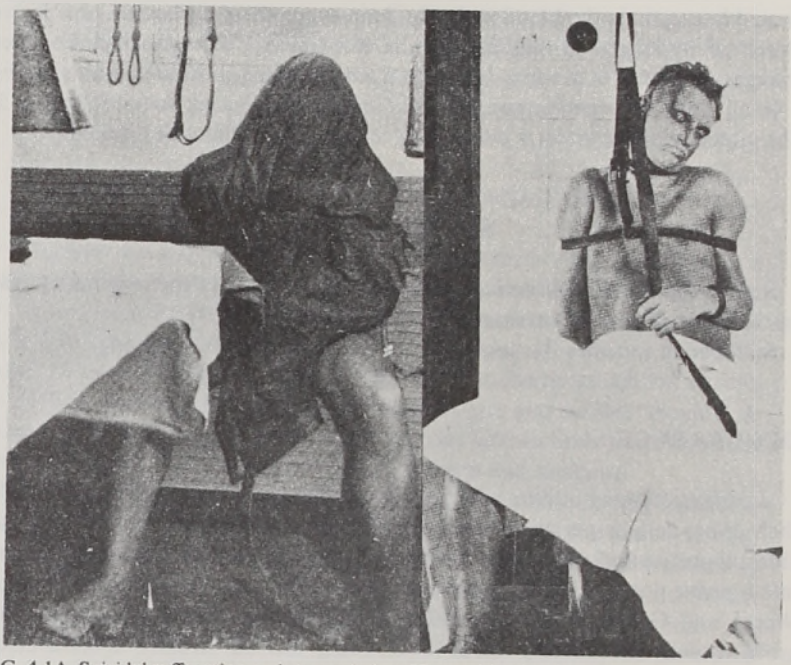

FIG. 4.1A. Suicidal suffocation and strangulation. The position in which the deceased was found.
FIG. 4.1B. Reconstruction of the position of the deceased after the removal of the oilskin (see text).

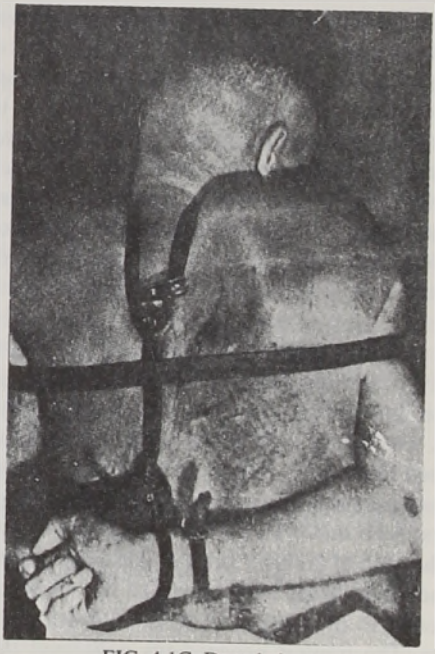

FIG. 4.1C. Dorsal view.

practised tying himself up in this unusual manner on several occasions before his death.

Homicidal. Homicidal suffocation is relatively uncommon in adults, but it may occur in cases where the victim is too feeble to offer any resistance because of old age or illness. Homicidal suffocation is also seen where persons are overpowered while asleep or intoxicated. In one of our cases of homicidal suffocation a storekeeper was attacked by several assailants. A handkerchief was forced into his mouth, and a blanket was placed over his head and tied into position by a towel in the manner shown in Fig. 4.2. Probably the best-known series of

FIG. 4.2. Homicidal suffocation.

murders by suffocation were those committed by the notorious criminals, Burke and Hare, in Scotland in the early part of the nineteenth century.[3] The method of smothering employed by these men, which has become known as 'burking', consisted of a combination of compression of the chest with the forcible closure of the mouth and nostrils. In these murders the victims were usually attacked while asleep or while lying helpless through intoxication. One of the assailants used to throw himself over the chest of the victim while the other forcibly closed the victim's mouth and nostrils with his hands.

Suffocation or smothering is one of the commonest methods of infanticide. An infant may be smothered without the use of much force by such means as the placing of a pillow or bedclothes or the palm of the hand over the nostrils and mouth. In the case shown in Fig. 4.3, a piece of cloth was tied over an infant's mouth and nose and then looped around the neck.

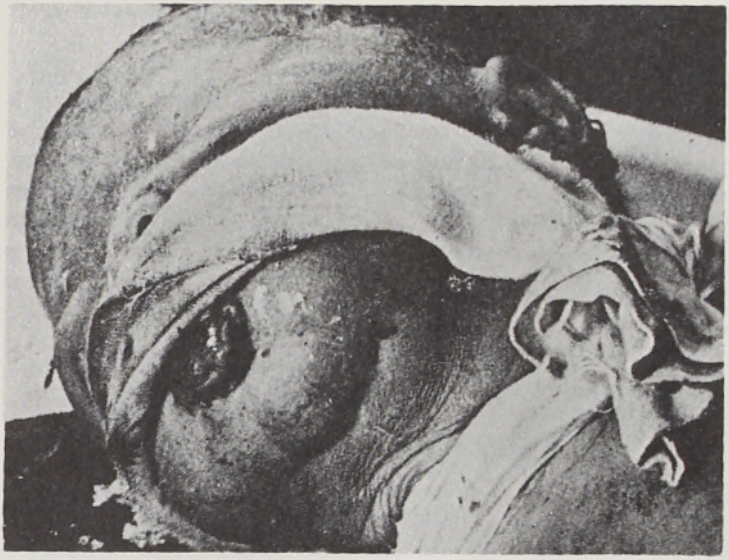

FIG. 4.3. Infanticide by suffocation and strangulation.

MECHANISM OF DEATH

Death is usually due to hypoxic hypoxia or anoxic anoxia.

AUTOPSY FINDINGS

Special Pathological Changes

Post-mortem Lividity. Under certain conditions the site of distribution of the lividity may be suggestive of suffocation, e.g. in the case of the infant dead in its cot (p. 21) the ventral distribution of the lividity suggested that the child might have been accidentally suffocated.

External Wounds in the Region of the Mouth and Nostrils. In homicidal suffocation abrasions and bruises are generally found in the region of the mouth and nostrils. These injuries are usually produced during struggling, but they may be absent in cases where the victim is unable to offer resistance or is rapidly overpowered, e.g. they may be absent in infants and young children and in aged and debilitated persons.

Non-specific General Pathological Changes

Non-specific general pathological changes as described in Chapter 3 are present. In most cases the intensity of the visceral congestive changes is marked. Numerous petechial haemorrhages are usually found in the pleurae and pericardium.

THROTTLING

Throttling or manual strangulation is the application of force to the neck of a person by pressure from the hands or forearm of another person.

OCCURRENCE

Death from throttling is almost invariably homicidal, but instances of accidental throttling have been recorded. Homicidal throttling occurs in the course of assaults, and in cases of robbery and rape. Cases of accidental throttling have been recorded where firm pressure has been suddenly applied to the neck of a person during an embrace or in the course of 'horseplay'. Such deaths are probably caused by a reflex cardiac arrest which is brought about by compression of one or both of the carotid sinuses (p. 132).

Suicidal throttling has not been recorded.

MECHANISM OF DEATH

Death from throttling may be due to one of the following mechanisms:

1. Pressure on the sides of the neck may constrict the larynx and prevent the free passage of air down the respiratory tract. This results in hypoxic hypoxia which can lead to rapid death.
2. Compression of one or both of the carotid sinuses can result in reflex cardiac arrest and instantaneous death (p. 132).
3. Obstruction of the carotid arteries and internal jugular veins can result in cerebral hypoxia. Death may result if the cerebral hypoxia is maintained for a sufficient length of time.

AUTOPSY FINDINGS

Special Pathological Changes

External Injuries—The nature and extent of the external injuries depend upon the method of throttling. An assailant may apply pressure to the neck with one hand, with both hands, or with his forearm. The assault may take place from the front, from the side, or from behind the victim. The pressure is most commonly applied to the upper part of the front of the neck. The soft tissues of the neck are not only compressed but they are forced upwards and backwards against the cervical vertebrae.

When the assailant uses one hand and the assault takes place from the front of the victim, the upper part of the neck immediately below the angles of the jaw is usually gripped. In such cases superficial bruises of the skin and crescentic abrasions, caused by fingernail impressions may be observed on both sides of the neck. The bruises and abrasions may be more numerous on one side of the neck than on the other side.

Gonzales[4] states that a single abrasion on the right side of the neck and grouped abrasions on the left side of the neck are suggestive of a right-handed

compression of the throat. The single abrasion is caused by pressure from the thumb and the grouped abrasions result from the pressure of the four fingers.

When an assailant using one hand changes his grip, or when he uses both his hands, multiple bruises and abrasions may be found over the front and sides of the neck (Figs. 4.4A and 4.4B).

FIG. 4.4A. Homicidal throttling. Injuries to the right side of the neck.

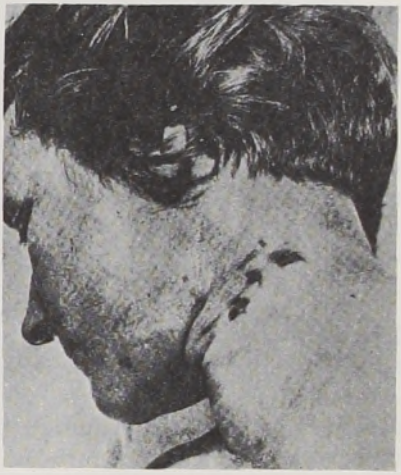

FIG. 4.4B. Same case as Fig. 4.4A. Injuries to the left side of the neck.

In certain circumstances there may be no external evidence of injury on the neck. This occurred in one of our cases, described on page 45, where the accused placed a thick towel over the neck of his wife and throttled her through the towel.

When the assailant uses his forearm in throttling, the assault usually takes place from behind the victim. Pressure is exerted by the forearm against the arm of the assailant, and the larynx is compressed. In such cases external injuries are usually absent.

Injuries to the Cervical Tissues. Bruises may be found in the deeper layers of the skin, in the superficial fascia, in the deep fascia, in the sheaths of muscles, in the cervical muscles, and under the capsule and in the substance of the thyroid gland, and less commonly under the capsules and in the substance of the submandibular glands. Bruises may be observed in the retropharyngeal tissues and at the base of the tongue. Section of lymph nodes may show haemorrhages into their substance.

Injuries to the Hyoid Bone and the Laryngeal Cartilages. Fractures of the hyoid bone are commonly found in throttling. In order to demonstrate the presence of a fracture it is essential to expose the hyoid bone. A fracture appears as an irregular break in the continuity of the bone and is usually accompanied by haemorrhage at the site of fracture. The greater horn of the hyoid bone is united

to the body of the bone by a plate of cartilage which ossifies at middle age. Romanes[5] states that the lesser horn is united to the body and the greater horn by a synovial joint which only disappears in old age. The cartilaginous separations between the greater horns and the body, and the joints between the lesser horns and the body should not be mistaken for fractures.

Fractures of the hyoid bone are not invariable in throttling, particularly in young persons. When fractures of the hyoid bone are found, it is highly suggestive of throttling as it is exceptional for the bone to be injured when other forms of blunt force are applied to the head and neck.

The laryngeal cartilages are less commonly injured than the hyoid bone, and it is unusual for these structures to be fractured before they have undergone ossification. Anson[6a] states that:

> ... certain parts of the laryngeal skeleton normally undergo calcification and ossification. Calcification begins at about 20 years of age in the thyroid and cricoid cartilages, and later in the arytenoid. The process begins a little later in the female than in the male, and does not extend so rapidly. The extent to which the cartilages are ossified and the time occupied in the process vary considerably. The elastic elements usually are not involved in the process. Calcification of the smaller cartilages, especially, is important clinically because such calcific areas may be mistaken for foreign bodies in roentgen examinations.

The foregoing statement is supported by the observations of Keen and Wainwright.[6b]

In order to demonstrate the presence of fractures of the laryngeal cartilages it is essential to strip the larynx of its attached muscles and ligaments. Bruises of the laryngeal mucous membrane occur in throttling and may or may not be accompanied by fractures of the hyoid bone and laryngeal cartilages.

Camps and Hunt,[6c] however, report the following case:

> We have also seen a fracture of the superior thyroid cornu in a man dying of ascending pyelonephritis in a hospital ward. There was no question of any ante-mortem violence, but the laying-out of the body was admitted to have been done very roughly with hyperextension of the neck. Furthermore, there was a localised post-mortem extravasation of blood around the fracture. This would, in less certain circumstances, undoubtedly have been considered good evidence that the injury occurred before death, and illustrates the care required in interpreting such injuries.

Obstruction to the Venous Return from the Head and Neck. Signs of mechanical obstruction to the venous return from the head and neck may be present. These signs include the following: Lividity of the face and lips; engorgement and petechial haemorrhages in the conjunctivae; and petechial haemorrhages in the skin of the face and neck.

Other Injuries. Bruises and abrasions may be found on other parts of the body. In cases where the victim has been forced to the ground and has been held down, areas of bruising may be found in the following regions: in the scalp tissues over the back of the head; in the tissues overlying the spinous processes of the lower cervical and upper dorsal vertebrae; and in the tissues overlying the posterior surfaces of the shoulder blades. Bruising of the muscles of the anterior chest and abdominal walls may be found in those cases where the assailant has knelt upon the victim. When considerable force has been used, ribs may be fractured and contusions and ruptures of the abdominal viscera may occur.

Non-specific General Pathological Changes

Non-specific general pathological changes as described in Chapter 3 are present. In most cases the intensity of the visceral congestive changes is marked and numerous petechial haemorrhages are found in the pleurae and pericardium.

ADDITIONAL POINTS OF MEDICO–LEGAL IMPORTANCE

The Significance of Fingernail Abrasions of the Skin

Characteristically grouped crescentic abrasions of the skin are quite rightly regarded as good evidence consistent with the manual application of force to the part. Shapiro, Gluckman and Gordon[7] state that within their experience, medical experts have sought to draw inferences about the way in which the hand was applied to the neck in throttling, from the direction of the concavity of this type of abrasion. It has been assumed that, if the right hand of the assailant is applied to the neck of the victim from in front (i.e. with the assailant's right thumb on the right side of the victim's neck, and the remaining fingers of the assailant on the left side of the victim's neck) then the concavities of the crescentic abrasions will all face medially. This appears to be a plausible, common-sense view, but when tested, it was shown that the results were completely contrary.

Fig. 4.5A illustrates the position of the fingers of an 'assailant' on the front of the left forearm immediately before compression of the forearm. Fig. 4.5B illustrates an early stage in the actual compression. It would be reasonable to expect

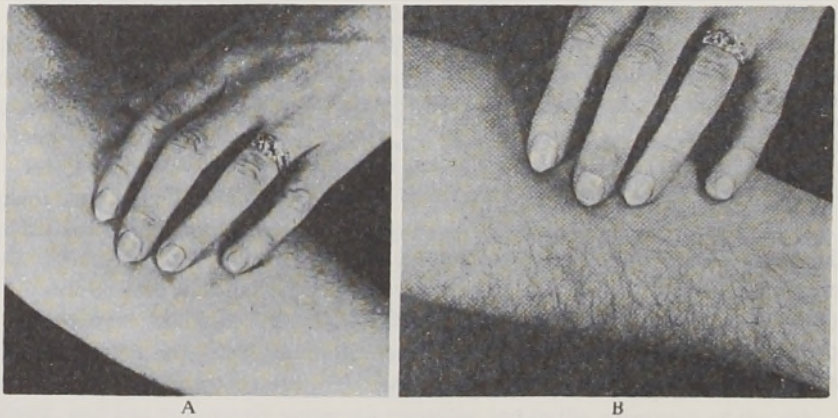

A B

FIG. 4.5A. This photograph illustrates the position of the fingers of an 'assailant' on the front of the left forearm immediately before compression of the forearm.

FIG. 4.5B. This photograph illustrates an early stage in the actual compression of the forearm.

that the concavity of each crescentic abrasion would be directed to the outer (radial) border of the forearm. Fig. 4.5C illustrates the actual appearance of the crescentic abrasions obtained. It will be noted that the concavities of the crescentic abrasions are all directed towards the inner (ulnar) border of the forearm, i.e. in the opposite of the anticipated direction.

Experiments with numerous subjects have demonstrated that this is not unusual but quite a common finding. In some cases a linear impression is obtained, but it is by no means usual for the concavity to follow the anatomical shape of the nail margin.

From an examination of this problem we have concluded that the shape of the finger nail largely determines the result. Nails with a straight border give unpredictable results; but as they become more pointed towards the centre of the free border, so do the apparently paradoxical results occur more frequently.

FIG. 4.5C. This photograph illustrates the actual appearance of the crescentic abrasions obtained. It will be noted that the concavities of the crescentic abrasions are all directed towards the inner (ulnar) border of the forearm, i.e., in the opposite of the anticipated direction.

The unexpected direction of the concavity is determined by the anchoring of the skin of the victim by the central portion of the assailant's finger nail, thus displacing the skin so as to produce the reversed crescent. The sides of the free edge of the arch of the finger nail, in their contact with the skin, have no purchase and merely complete the sides of the concavity.

These observations indicate that it is extremely fallacious to infer the way in which an assailant's hand may have been applied to the part, from the direction of the concavities of crescentic abrasions.

Diagnosis of Throttling in Putrefied Bodies

With the development of putrefaction and the associated progressive discoloration of the skin, it becomes increasingly difficult to detect external injuries in the neck. A similar difficulty arises in the diagnosis of bruises in the decomposed deeper cervical tissues. Although the discolorations produced in decomposing bruises are usually localized, similar areas of discoloration may be found when putrefaction affects localized ante-mortem intravascular collections of blood in the cervical tissues, or localized patches of post-mortem lividity. These difficulties have been considered in detail in connection with the case described at pages 37–39. It is particularly important to examine the hyoid bone for fractures in putrefied bodies, as such a finding is usually strongly suggestive of throttling (p. 81).

Post-Mortem Dissection Artefacts of the Neck and their Differentiation from Ante-Mortem Bruises

The handling of organs and the incision of vessels during routine post-mortem examinations often result in the extravasation of blood into the tissue spaces. These extravasations have been described as dissection artefacts, and their occurrence in cervical tissues is of special importance as they simulate ante-mortem bruises.

In dealing with the tissues of the neck in the routine post-mortem examination it is usual to reflect the skin by a subcutaneous dissection through the platysma muscle. This method of dissection ensures a clear exposure of the subcutaneous tissues and the ventral surfaces of the superficial muscles of the neck. It is not common practice to reflect individual cervical muscles from their attachments in order to expose the deeper structures of the neck. After the initial subcutaneous dissection, structures of the neck are usually removed *en masse* by downward traction from the floor of the mouth. The structures of the neck are then examined individually. In order to study the incidence and nature of dissection artefacts of the neck, Prinsloo and Gordon[8a] followed this method of dissection in 18 cases. At the time of the initial dissections no extravasations of blood were observed in the subcutaneous tissues or in the fascia overlying the ventral surfaces of the superficial muscles. After the *en masse* removal of the structures however, extravasations of blood were found in the deep connective tissues in 16 of the 18 cases. Although there was no evidence or suggestion of any ante-mortem cervical injury in these cases, there was no means of determining whether these extravasations were bruises or post-mortem artefacts. Accordingly, the method of dissection described on page 52 was devised to ensure that all the tissues of the neck were inspected *in situ* before removal. This method of dissection was carried out in 33 cases. Areas of extravasation of blood which were not seen at the time of the initial dissections, and were therefore produced after the dissections during the handling of the structures of the neck, were found in 20 of the 33 cases. In all instances the dissection artefacts simulated bruises. The dissection artefacts were found in the following situations: in the pretracheal connective tissues; in the investing fascial sheaths of the cervical muscles; in and around the carotid sheaths; in the capsule of the thyroid gland; and in the prevertebral or retropharyngeal connective tissues. The general appearance of a dissection artefact is shown in Fig. 4.6.

In view of the similarity in the naked-eye appearance between ante-mortem bruises and dissection artefacts, Prinsloo and Gordon examined selected bruises and dissection artefacts microscopically. Figures 4.7 and 4.8 show that on microscopic examination it is not possible to distinguish between dissection artefacts and ante-mortem bruises caused shortly before death.

A large number of deaths which have to be investigated for forensic purposes occur in circumstances in which there is inadequate information relating to the events which have preceded the deaths. Many of these deaths are due to natural causes, and in the majority of this group, some lesion is found which is compatible with continued life, but which is also known to be associated with sudden death, e.g. coronary atheroma.

It is well recognized that external injuries and injuries to the hyoid bone and laryngeal cartilages may be absent in cases of homicidal throttling, and in such cases the demonstration of bruises in the deeper cervical tissues is essential for diagnosis. For this reason a difficult problem may arise when areas of extravasated blood are found in the cervical tissues in the course of a routine post-mortem examination which reveals some lesion which is compatible with sudden death from natural causes, but which is also compatible with continued life. If the extravasations of blood are bruises, then the possibility of the death having been caused by throttling must be considered, in spite of the presence of the pathological lesion. On the other hand unless an inspection of all the cervical

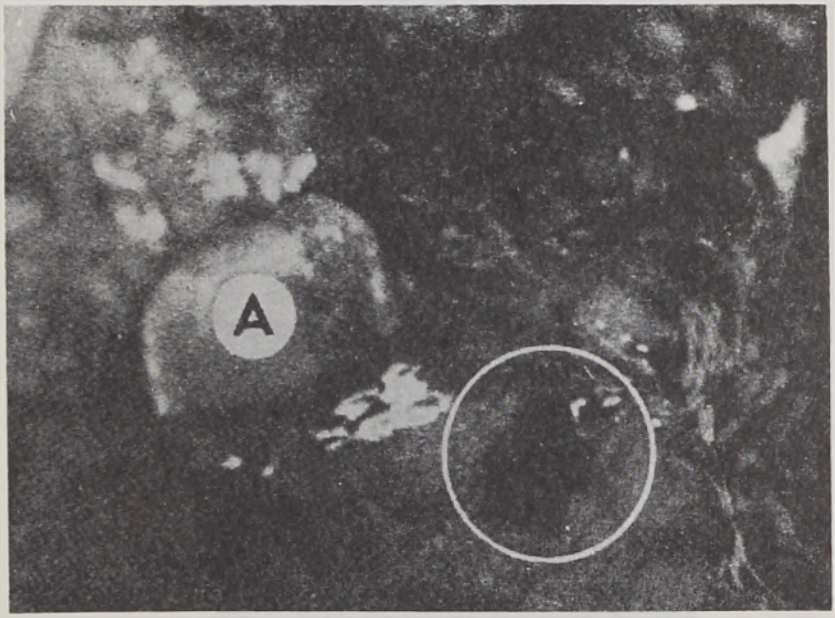

FIG. 4.6. Dissection artefact underlying right greater horn of hyoid bone. The dissection artefact is encircled in white.
A, Posterior surface of the epiglottis.

tissues has been undertaken *in situ* it might be impossible to prove that the extravasations of blood are not dissection artefacts. The only certain method of ensuring that post-mortem artefacts are not mistaken for ante-mortem bruises is to examine all the structures of the neck *in situ* as a routine procedure in all deaths which have to be investigated for medico–legal purposes.

STRANGULATION

Strangulation is a constriction of the neck by a ligature, the constricting force being applied directly to the ligature.

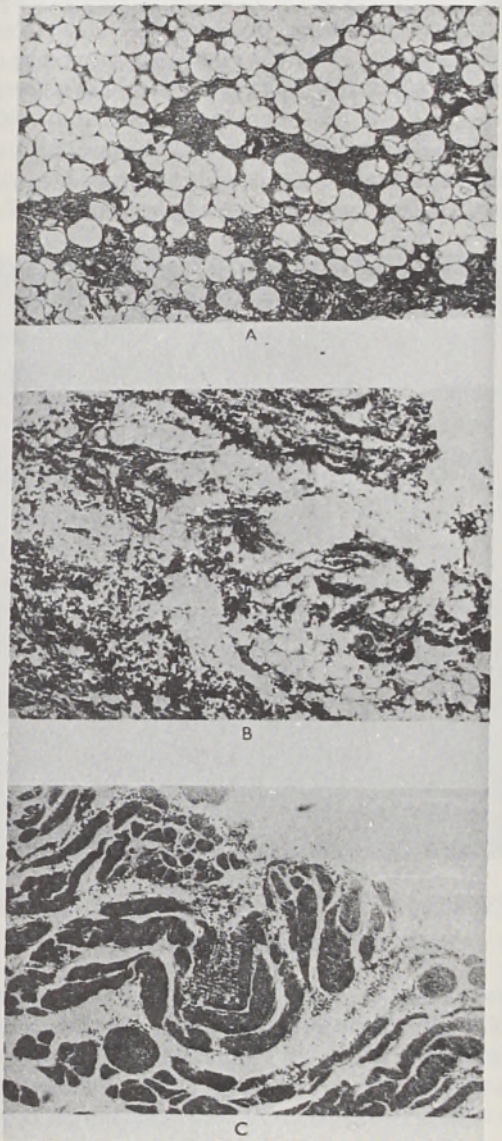

FIG. 4.7. A, Dissection artefact in the superficial fascia; B, Dissection artefact in the deep fascia. Note the extravasation of erythrocytes between the collagen fibres; C, Dissection artefact in muscle. Note the extravasation of erythrocytes over the surface of and between the muscle fibres. (Haematoxylin and eosin. × 290).

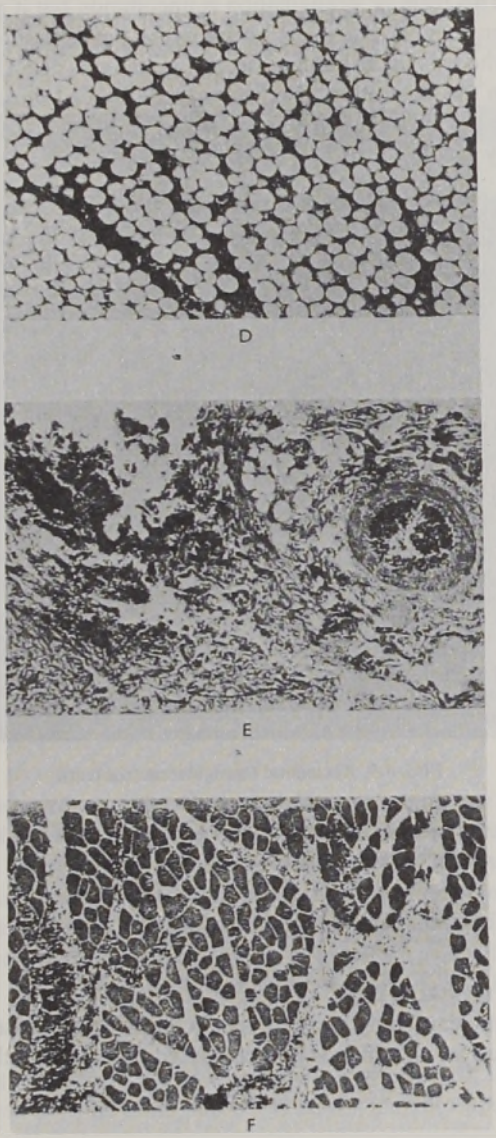

FIG. 4.8. D, Ante-mortem bruise in superficial fascia; E, Ante-mortem bruise in deep fascia; F, Ante-mortem bruise in muscle. (Haematoxylin and eosin. × 290).

OCCURRENCE

Accidental. This form of strangulation is uncommon but it may occur under special conditions, e.g. in intoxicated persons. In the case shown in Fig. 4.9 a drunk person who was in the habit of sleeping next to his dog, climbed under the staircase seen in the illustration. He then pushed his head through a loop in the dog's chain which was fastened to the lower step of the staircase. In this way he was accidentally strangled.

FIG. 4.9. Accidental strangulation (see text).

Suicidal. This form of strangulation is rare. A case of suicidal suffocation and strangulation has been described on page 75.

Homicidal. Homicidal strangulation is relatively common.

MECHANISM OF DEATH

Death is usually caused by anoxic hypoxia but in certain cases it may be due to a reflex cardiac arrest which is induced by compression of the carotid sinus (p. 132).

AUTOPSY FINDINGS

Special Pathological Changes

The External Ligature Mark

General Appearance. A single external ligature mark is usually present on the neck, but more than one mark may be found. These marks take the form of linear

depressions in the skin, and their general appearance depends mainly upon the nature of the ligature material. Ligature marks are most distinct in cases where the ligature used is made of hard material such as coarse roping or wire (Figs. 4.10 and 4.11). On the other hand, the marks may be indefinite in cases where the

FIG. 4.10. Homicidal strangulation. The ligature mark is seen on the right side of the neck above the collar band of the shirt.

ligature used is made of soft material. This condition was seen in one of our cases where a folded blanket was used as a ligature. It was also seen in one of our cases of infanticide where a stocking was used as a ligature (Fig. 4.12).

Ligature marks are usually brown and dry at the time of examination, while abrasions and bruises of the surrounding skin are commonly found in relation to them (Fig. 4.13). These abrasions and bruises are caused occasionally by the victim's finger-nails in cases where an attempt has been made by the victim to release the ligature.

Situation. The ligature marks may be situated in any region of the neck, but they are usually found over the lower part of the larynx and the upper part of the trachea.

Direction. The marks are usually directed transversely across the neck.

Injuries to the Tissues of the Neck

Dissection of the neck usually reveals a moderate degree of bruising to the connective and muscular tissues, but such bruising is not an invariable finding.

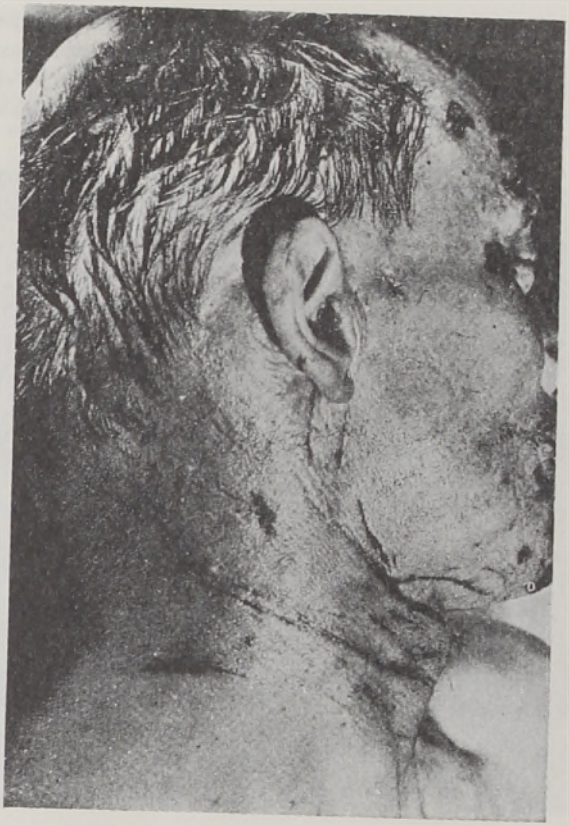

FIG. 4.11. Homicidal strangulation.

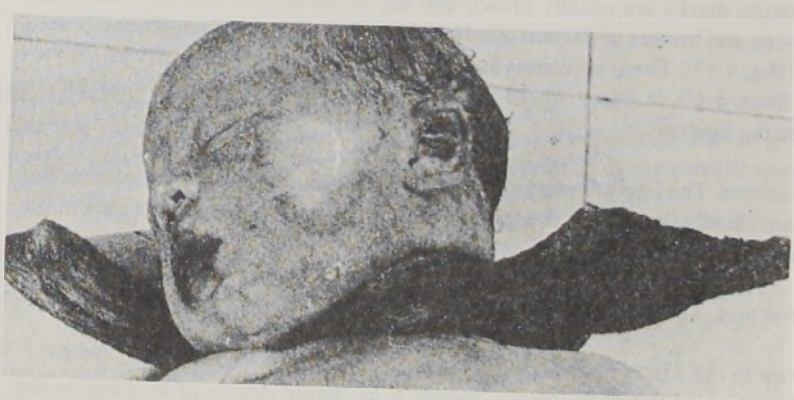

FIG. 4.12. Infanticide by strangulation.

In the case illustrated in Fig. 4.14 the deceased was strangled with his own scarf. The scarf was found tied tightly around his neck. Although a broad depression was observed at the site of pressure of the scarf there were no abrasions or bruises of the surrounding skin. Dissection failed to reveal any bruising in the connective or muscular tissues of the neck and there was no injury to the hyoid bone or the laryngeal cartilages.

FIG. 4.13. Infanticide by strangulation (see text).

FIG. 4.14. Homicidal strangulation.

Injuries to the Hyoid Bone and the Laryngeal Cartilages

Fractures of the hyoid bone are unusual in strangulation. Fractures of the laryngeal cartilages occur, but they are relatively uncommon. Injuries to the mucous membrane of the larynx are less common in strangulation than throttling.

Obstruction of the Venous Return

Signs of mechanical obstruction to the venous return from the head and neck may be present. These signs have been described on page 81.

Non-Specific General Pathological Changes

Non-specific general pathological changes as described in Chapter 3 are present. The intensity of the visceral congestive changes is usually well marked.

ADDITIONAL POINTS OF MEDICO–LEGAL IMPORTANCE

Differentiation between Homicidal Strangulation and Accidental Strangulation by the Umbilical Cord in Infants

In newly born infants it may be difficult to distinguish between homicidal strangulation and an accidental strangulation by the umbilical cord during the process of birth. This difficulty is increased when the cord is used as a ligature for homicidal purposes.

As a general rule, in the accidental form of strangulation by the umbilical cord there is relatively slight cervical tissue injury, while the lungs are usually incompletely expanded. In this connection, it should be noted that marked bruising of the cervical muscles may be produced during the ordinary course of labour. The presence of a complex type of knotting in the cord, e.g. the finding of a reef knot, suggests the homicidal form of strangulation.

Retention of Ligature in Cases of Homicidal Strangulation

In cases of strangulation the ligature should be kept for examination. If possible, the ligature should be taken off in such a way that the knot is retained intact. If the knot is situated over the front of the neck the ligature can be cut behind the neck and vice versa.

CASE OF HOMICIDAL STRANGULATION

Some years ago, an unusual case of alleged homicidal strangulation occurred in Natal:

A woman attended a beer-drinking party at a kraal. She was seen leaving the party during the night, and the following morning she was found dead about two miles from the kraal in a donga (a shallow gully or ravine). She was lying in a prone position with her mouth and nostrils buried in a pool of mud. There was evidence that she was under the influence of alcohol when she left the party, and it was concluded that she had fallen into the donga accidentally and had become suffocated in the mud.

No injuries were observed on external examination of the body, and as foul play was not suspected the deceased was buried without a post-mortem examination being held. Within a few days a young man made a voluntary statement to the police, in which he alleged that the deceased

had been murdered. He stated that some months before her death the deceased had reported a headman to the police for committing adultery. The headman was prosecuted, and subsequently told several of his friends that he would avenge himself upon the deceased for this disclosure. The informant stated that on the night of her death he saw the deceased leave the kraal, and he noticed that she was followed by two men. He recognized one of the men as the headman, and he saw them both attack the woman. He said that they tied a folded blanket around her neck in such a way that they each held one of the ends. They then forced her into the donga, and took up positions on opposite banks. They pulled the deceased along by the blanket until she collapsed, and after she had fallen they removed the blanket from her neck and left her lying in the donga.

Upon this information an exhumation was ordered. The tissues of the neck were dissected and some evidence of bruising was observed, but the findings were obscured by putrefactive changes. No other cause of death could be found at the autopsy and strangulation was given as the probable cause of death, in spite of the absence of any external evidence of injury to the neck.

The failure to perform a post-mortem examination soon after death in this case provided a degree of uncertainty as to the cause of death, and seriously hampered the Crown in its prosecution. This case illustrates the need for holding complete autopsies as soon as possible in all reported sudden deaths.

HANGING

Hanging is a constriction of the neck by a ligature, the constricting force being applied indirectly to the ligature through the weight of the body.

In hanging, the body is usually wholly suspended with the feet above the ground, but hanging can occur with the body in a position of partial suspension. In the case shown in Fig. 4.15, the deceased hanged himself in a sitting posture. It is possible that consciousness is lost rapidly in cases of this nature.



FIG. 4.15. Suicidal hanging.

OCCURRENCE

Accidental. This form of hanging is uncommon, but cases have been recorded where children at play have hanged themselves, and where workmen in falling from scaffolding have been hanged by becoming entangled in ropes.

Suicidal. This is the commonest form of hanging. One of our cases of suicidal hanging is shown in Figs. 4.16A and 4.16B. This case was unusual in regard to the manner in which the deceased tied the rope around his body before he hanged himself.

Homicidal. This form of hanging is rare.

MECHANISM OF DEATH

Death can be due to hypoxic hypoxia or anoxic anoxia, the obstruction to the airway being caused by the upward displacement of the base of the tongue

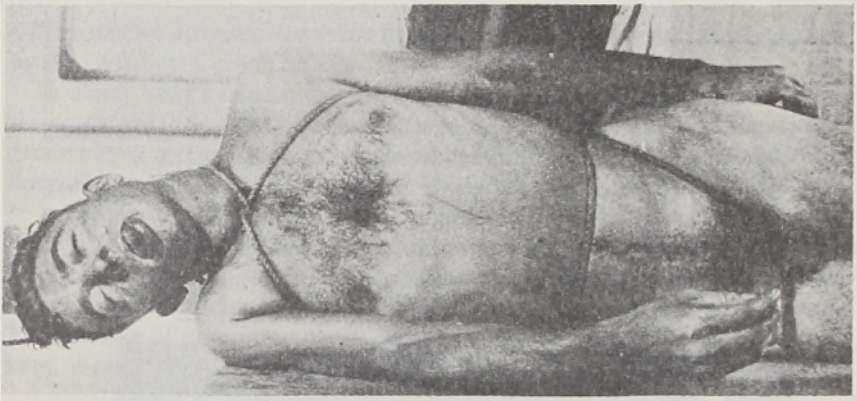

FIG. 4.16A. Suicidal hanging. Ventral view.



FIG. 4.16B. Same case as Fig. 4.16A. Dorsal view.

against the palate and the posterior pharyngeal wall. In certain cases, however, death may be due to a reflex cardiac arrest which is induced by compression of the carotid sinus (p. 132).

Fracture-dislocations of the cervical vertebrae may occur in certain types of hanging, e.g. in judicial hanging, and in cases of suicidal hanging where the deceased has jumped from a height and the fall has been arrested by a sudden jerk of the ligature.

AUTOPSY FINDINGS

Special Pathological Changes

Post-mortem Lividity. In cases of complete suspension lividity is usually observed in the dependent lower limbs and in the hands. In males there may be considerable engorgement of the penis and testes.

The External Ligature Mark

General Appearance. A single ligature mark is usually present on the neck. The ligature, however, may be composed of a double strand or of several strands, and in these cases more than one mark will be observed on the neck.

A ligature mark is usually depressed below the skin surface, and it often corresponds in outline to the pattern of the ligature. In the early period after death the mark is pale in colour, but it later becomes brown and dry. Abrasions and bruises of the skin are occasionally seen in the bed of the depression, but there is usually no evidence of injury to the skin surrounding the ligature mark. Patches of lividity are often found immediately above the upper border of the mark. The general appearance of a ligature mark in a case of suicidal hanging is shown in Fig. 4.17.

Situation. The mark is usually situated over the upper part of the larynx but it may be lower in cases of partial suspension.

Direction. The direction of the ligature mark depends upon the type of ligature which has been used in the hanging.

Ligatures are usually tied in the form of fixed loops with single knots, but the knots may be multiple. In certain types of hanging a running noose ligature is used.

When a fixed loop is employed with a single knot in the midline either under the chin or at the back of the head, the mark is seen on both sides of the neck and is directed obliquely upwards towards the position of the knot over the front or back of the neck, as the case may be. When a fixed loop is used with the knot in the region of one ear, the mark differs on each side of the neck. On the side where the knot is situated the mark is directed obliquely upwards towards the knot, whereas it is directed transversely on the other side. When a running noose is employed the mark is seen on both sides of the neck, and is usually directed transversely across the front of the neck.

difficult, as a well-defined ligature mark and bruising of the subcutaneous tissues may be produced after death.

In distinguishing between these two conditions:

1. It is important for the medical practitioner to arrange with the police in his district to inspect the place where the alleged hanging took place. At such an inspection the medical practitioner should determine whether the victim could have suspended himself in the manner in which he was found.

2. The autopsy should be complete, as some cause of death other than hanging is usually found in cases where a body has been suspended after death to simulate suicide. Difficulty may arise, however, in cases where bodies are suspended after homicidal strangulation or throttling.

3. A portion of the skin and deeper tissues in relation to the ligature mark should be examined histologically for evidence of tissue reaction. This investigation would only be of value in a case of hanging if the period of time that elapsed before death was sufficiently long for tissue reaction to develop (p. 211). The presence of tissue reaction in these circumstances would suggest that the deceased had been hanged. The absence of tissue reaction, however, does not exclude death by hanging.

CHOKING BY FOREIGN–BODY IMPACTION

Death from choking may result from the impaction of foreign bodies in the pharynx, larynx, trachea or bronchi.

OCCURRENCE

Most deaths from choking are accidental. Children often place objects such as marbles or coins in their mouths and these objects may pass into the larynx or trachea during a sudden deep inspiration. Accidental deaths from choking are not uncommon in mental hospitals as persons with disordered or defective minds often cram large portions of food into their mouths (p. 132). Eller and Haugen[8b] record that about 700 to 1000 deaths by 'choking on food' occur annually in the United States of America—as proved at autopsy. The National Safety Council of the United States has added 'Inhalation of Food' to its compilation of accidental deaths and estimates nearly 2500 such fatalities annually—more than those due to aircraft accidents, firearms, lightning and snakebite. 'Inhalation of Food' is the sixth leading cause of accidental death in the United States of America.

The impaction of loose bodies such as surgical swabs in the larynx, trachea or bonchi while a patient is under the influence of a general anaesthetic may result in rapid death (p. 158). In cases of stupor, e.g. from acute alcoholic intoxication, death may be caused by the impaction of a denture in the pharynx or larynx.

Homicidal deaths by choking are uncommon, but cases may occur when the victims are aged or debilitated persons or are infants. In one of our cases of infanticide, a portion of cloth was forced into the upper end of the oesophagus of the infant and was found *in situ* at the autopsy (Fig. 4.18). The mouth, palate and

pharynx of an infant should always be carefully examined for injuries at autopsy in a case of this nature, as the foreign body is often removed by the assailant after death.

FIG. 4.18. Infanticide. Impaction of cloth in upper portion of oesophagus. C, Oesophagus; D, Base of tongue.

MECHANISM OF DEATH

Large foreign bodies often become impacted in the pharynx and cover the laryngeal opening. By obstructing the airway completely such impacted bodies may cause death through hypoxic hypoxia or anoxic anoxia. Smaller foreign bodies which lodge in the larynx may not be large enough to obstruct the airway completely, but they may induce a laryngeal spasm. As a general rule laryngeal spasm passes off before the hypoxia becomes fatal. Sudden reflex neurogenic cardiovascular failure may occur in both forms of laryngeal obstruction. The cardiovascular failure is probably induced by reflex parasympathetic cardiac inhibition (p. 132).

If a foreign body passes through the larynx it may become impacted at the bifurcation of the trachea or it may lodge in a bronchus. When a foreign body impacted at the bifurcation of the trachea obstructs the free passage of air into the lungs, death may be caused by hypoxic hypoxia or anoxic anoxia, but irritation in this region is particularly liable to induce parasympathelic cardiac inhibition (p. 132).

Reflex cardiac inhibition may also occur when a foreign body is impacted in a bronchus. In one of our cases, a child, aged 3 years, 'choked' when eating a sausage. He appeared to recover but shortly afterwards, while resting, he suddenly became pale and died without showing any signs of respiratory dis-

tress. At the autopsy, there was a striking absence of visceral congestion and a portion of sausage was found in the right bronchus.

The impaction of a foreign body in the larynx, trachea or bronchi may give rise to severe reflex bronchiolar spasm. In one of our cases a youth participated in an obstacle race. Towards the end of the race each of the competitors had to eat an apple suspended from a string. While eating the apple the youth 'choked' and as he showed signs of respiratory distress he was taken to hospital. The signs of respiratory distress passed off before he reached the hospital and on examination no abnormality was observed on laryngoscopy or on radiological examination of the chest. He was discharged after a short period, but within an hour of leaving the hospital he rapidly developed signs of intense bronchospasm and died. No organic disease was detected at the autopsy, but several pieces of apple were found in the trachea.

The impaction of foreign bodies in the respiratory tract, especially in the bronchi, may result in delayed death from pneumonia, lung abscess or bronchiectasis.

DROWNING

Drowning is a form of death in which there is defective oxygenation of the blood in the lungs, due to the presence of fluid in the respiratory tract, the fluid entering the air passages through the nose and the mouth.

Complete immersion is usual in drowning but intoxicated, unconscious or epileptic subjects may drown in a fluid medium which covers their nostrils and mouth only.

OCCURRENCE

Accidental. This is the commonest form, and is seen in the drowning of bathers, fishermen, dock workers, and intoxicated and epileptic subjects.

Suicidal. This type of drowning is fairly common. It should be noted that a determined suicide may tie his hands and legs together or attach weights to his body before immersion. These findings, therefore, are compatible with suicide unless it can be shown that the deceased could not have tied himself up in the manner in which he was found.

Homicidal. This form of drowning is rare, but cases have been recorded, e.g. 'The Brides in the Bath' case, Rex *v.* G. J. Smith (114 L.T. 239 Court of Appeal, 29th July, 1915).[9]

MECHANISM OF DEATH

Death is usually due to hypoxic hypoxia or anoxic anoxia but it may occur through reflex neurogenic cardiovascular failure (p. 126). The difficulties which

arise when attempts are made to relate speculative theories about the mechanism of death to post-mortem findings have been considered in detail by one of us.[10]

AUTOPSY FINDINGS IN NON-PUTRID BODIES

General Observation

It is essential to exclude from any description of anatomical signs as presumptive evidence of drowning, all signs of submersion or immersion such as goose skin (or cutis anserina) and sodden and wrinkled feet and hands (in the case of the hands, the so-called 'washerwoman's hands') (Fig. 1.10C). These signs have no evidential value in determining whether or not a person was breathing at the time of his submersion or immersion.

Special Pathological Changes

The Respiratory Tract. The characteristic signs of drowning are found in the respiratory tract. Frothy fluid which is often tinged with blood is observed in the bronchi, trachea and larynx and may appear about the mouth and nostrils. The lungs are usually voluminous. Petechial haemorrhages may be found in the pleurae. Section of the lungs may reveal a condition of marked congestion, while large amounts of frothy fluid may be expressed from their cut surfaces. Fluid may be present in the pleural cavities.

The frothing of fluid in the respiratory tract is the most characteristic sign of drowning, but if artificial respiration has been performed, particularly by means of a respirator, the frothing and the amount of fluid in the air passages may be considerably reduced.

The trachea and bronchi and the alveoli of the lungs may contain substances such as sand or shell particles which are ordinarily found in the medium in which the person has drowned.

The Stomach and Intestines. Fluid characteristic of the medium in which the drowning has taken place may be found in the stomach and intestines. This sign has a limited value however, as fluid may enter the stomach and small intestine after death if the pressure of the fluid in the medium is sufficiently great.

Non-specific General Pathological Changes

Non-specific general pathological changes as described in Chapter 3 are present. The intensity of the visceral congestive changes is usually well marked except in the voluminous lungs.

AUTOPSY FINDINGS IN PUTRID BODIES

The changes which are found in the tissues in putrefaction have been described in Chapter 1. Although the lungs tend to putrefy more slowly than the other viscera, they ultimately undergo a process of softening and liquefaction, and this change is usually accompanied by an extravasation of blood-stained fluid into the air passages and pleural cavities. In addition, the gases which are evolved

during putrefaction may pass into the fluid in the air passages and produce an appearance simulating the frothing which is found in drowning. For this reason it is usually impossible to determine whether a person has been drowned or not if the body is recovered in a state of advanced putrefaction. A presumption against drowning may be raised, however, if an injury which is incompatible with life is found on dissection of the body, provided that it can be shown that the injury could not have arisen after death.

ADDITIONAL POINTS OF MEDICO–LEGAL IMPORTANCE

Chemical Methods for the Determination of Death by Drowning

The various chemical methods which have been used for the determination of death by drowning have been reviewed by Moritz.[11] In most of these methods attempts have been made to detect chemical changes in the blood which depend upon an exchange of water and electrolytes between the inhaled fluid and the blood in the pulmonary capillaries. The best-known and most widely used of these methods is the method introduced by Gettler.[12] Gettler estimated the chloride content of the blood in the right and left ventricles in cases of drowning and compared his findings with a series of controls on persons who died of causes other than drowning. According to Gettler, the demonstration of a difference of at least 25 mg in the chloride content of the blood in the left and right sides of the heart provides evidence of drowning. In normal circumstances the chloride content of the blood is the same in both sides of the heart. When water enters the lung alveoli in large amounts the chlorides may diffuse between the inhaled fluid and the blood in the pulmonary capillaries. If the drowning has taken place in fresh water, the percentage of chlorides in the pulmonary capillaries is lowered, whereas the percentage is raised when drowning occurs in salt water. The reduction or increase in chlorides will therefore be more marked in the blood returning to the left auricle than in the blood entering the right auricle.

In analysing Gettler's method Moritz states that a reduction in blood chlorides is a common post-mortem phenomenon—the longer the interval between death and the examination the greater the reduction. Moreover, the reduction does not necessarily progress at the same rate in the two sides of the heart. Differences in the chloride content of the blood in the right and left sides of the heart may therefore develop in deaths from causes other than drowning. Because of the reduction in the blood chlorides after death, post-mortem changes are more likely to simulate the effects of drowning in fresh water than in salt water. Mortitz states that if a body is examined within twelve hours of being recovered from fresh water, a disproportionate depression of the chlorides in the left side of the heart of 17 milli-equivalents or more per litre (i.e. 60.35 mg. Cl per 100 c.c.) should probably be regarded as presumptive evidence of drowning.

Blood chloride estimations obtained twelve or more hours after death from drowning in fresh water are of little diagnostic value. On the other hand a failure to find a significant difference in the chloride content on the two sides of the heart would not exclude drowning if the body has been recovered from fresh water.

Chloride determinations have greater diagnostic value in cases of suspected drowning in sea water. In 80 per cent of the cases of drowning in sea water reviewed by Moritz abnormally high chloride values were obtained. In most of these cases the chloride level was not only higher in the left side of the heart, but the differences between the two sides were greater than had been observed in the control series. Moritz states that 'a preponderance of chlorides in blood from the left side of the heart of 17 milli-equivalents or more per litre (i.e., 60.35 mg. Cl per 100 c.c.) constitutes presumptive evidence of drowning in salt water.'

If in suitable cases it is decided to submit samples of blood for chloride determination the samples should be taken separately from the right and left ventricles into dry tubes. About 10 ml of blood should be obtained from each ventricle, and whenever possible an estimate of the sodium chloride content of the medium should also be undertaken. Schwär[13] has drawn attention to factors other than the length of the post-mortem interval which can influence the results of chemical determinations, e.g. there may be a continuation of the fluid/electrolyte flow in the pulmonary vessels after respiratory movement has ceased.

The Significance of Diatoms in the Diagnosis of Death by Drowning

Diatoms and Fluid Media. Thomas, Van Hecke and Timperman[14] state that 'it is now generally accepted that, during drowning in water containing microscopic plankton (diatoms, algae, plant fibres, etc.) the latter penetrate in small quantity into the lung capillaries, reach the left heart and are thus dispersed throughout the body by the arterial circulation.' Certain of the diatoms have acid resistant silica shells. Thomas and his co-workers claim that if such diatoms can be demonstrated in tissues which can only be reached by the systemic circulation, e.g. the bone-marrow, a strong presumption is raised that the deceased was breathing at the time of immersion in a fluid medium. The bone-marrow of long bones such as the femur, the tibia and the humerus is examined. In collecting the bones for examination, particular care is taken to avoid a risk of contamination from the outside by diatoms present on the skin and clothing on the body. The following technique is adopted by Thomas and his co-workers:

> One or more long bones are extracted from the body. All soft tissues attached are cut off and the bone scrubbed thoroughly. Halfway along the shaft, for a distance of a couple of centimetres, a layer of bone is cut out to a depth of about 2 mm., by means of a machine tool. Alternatively one can also perform this operation in two different places nearer the epiphyses. This procedure effectively prevents contamination of the bone-marrow. The shaft is then sawn through at the sites marked out by the machine tool. The bone marrow can now be collected by means of a gynaecological curette of adequate size. Experience teaches that from 15 g. to 40 g. of marrow can thus be recovered. The marrow is placed in a Kjeldahl flask in which it is chemically digested by adding small quantities of nitric acid at a time. Sulphuric acid is contra-indicated because it produces precipitates which completely obscure the microscopic picture. Heating is best done with an ordinary Bunsen burner. The operation lasts 1–2 hours and yields a transparent yellow fluid with a supernatant disc of fat. The yellow fluid is next centrifuged. The deposit (usually hardly visible to the naked eye) is poured on to a slide and examined, while still wet, under a coverglass.

Figs. 4.19 and 4.20 have been taken from Thomas, Van Hecke and Timperman.[14] Fig 4.19 shows the dismembered left lower limb of a woman who was alleged to have committed suicide by drowning in a river. The lower limb was recovered after the body had become entangled in the propeller of a small boat.

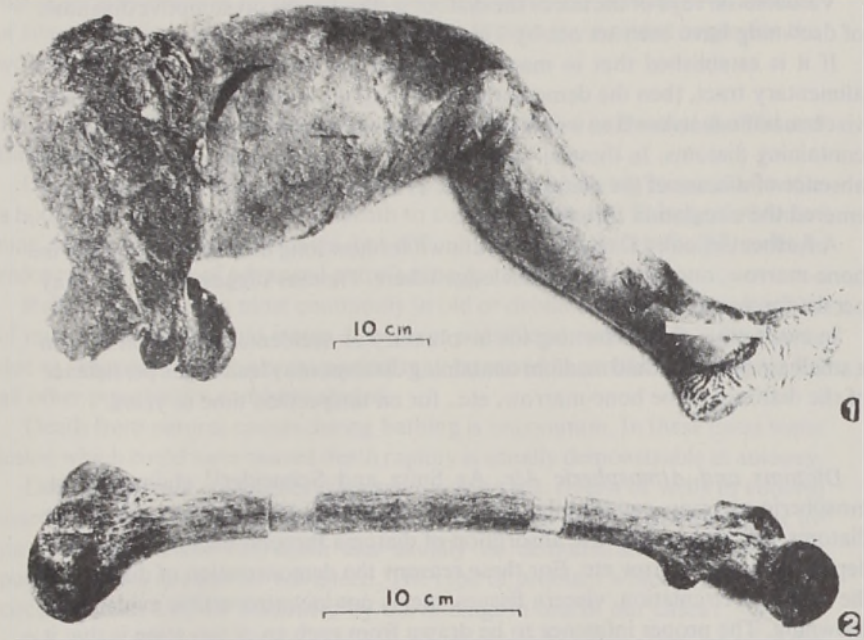

FIG. 4.19.
1. Dismembered left lower limb of a woman alleged to have committed suicide by drowning (see text).
2. Femur after removal of soft tissues and after preparation for collection of bone-marrow (see text).

Fig. 4.20 shows a variety of diatoms isolated from bone-marrow in cases of suicidal and accidental drowning. The figure shows the photomicrographs (at a magnification of 520) of two of numerous diatoms found in the bone-marrow of the femur in the case illustrated in Fig. 4.19—Nos. 5 and 6 of Fig. 4.20.

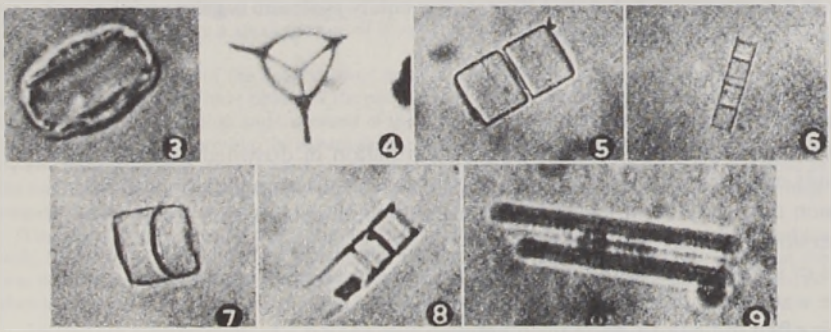

FIG. 4.20. Photomicrographs of diatoms recovered from bone-marrow collected from the femurs of drowned person 3 (× 1600; size of diatom: 12 μ × 9 μ), 4(× 440), 5 and 6 (× 520), 7 and 8 (× 900) and 9(× 1200).

Valuable surveys of the use of the diatom method in the presumptive diagnosis of drowning have been set out by Timperman.[15, 16]

If it is established that in man diatoms are not absorbed from the normal alimentary tract, then the demonstration of diatoms in the systemic circulation, viscera, bone-marrow etc., would be good evidence of the inhalation of a medium containing diatoms. In these circumstances, it will be necessary to establish the absence of disease of the alimentary tract as a result of which diatoms may have entered the circulation through the gut.

A further difficulty is that it is not known for how long diatoms remain, e.g. in bone-marrow, once they have been lodged there. Thomas suggests that they may persist for years.

In cases other than drowning the involuntary or accidental inhalation of even a small amount of a fluid medium containing diatoms may lead to the persistence of the diatoms in the bone-marrow, etc., for an unspecified time in years.

Diatoms and Atmospheric Air. As Spitz and Schneider[17] claim that atmospheric air may contain diatoms, inhalation of such a medium containing diatoms will also lead to the absorption of diatoms through the lungs and their deposit in bone-marrow etc. For these reasons the demonstration of diatoms in the systemic circulation, viscera tissues, etc. is not incontrovertible evidence of drowning. The proper inference to be drawn from such an observation is that it presents evidence of the inhalation of a medium containing diatoms whether the medium is water or air.

Diatoms and the Effects of Hydrostatic Pressure on Bodies recovered from the Sea-Bed. Nanikawa and Kotoku[18] describe their autopsy findings in a body recovered from the sea-bed at a depth of 120 metres. Their findings suggested that the body was that of an adult male who probably died of natural causes and was buried at sea. Diatoms found in the lungs were considered to have reached the lungs after death.

This finding is in accord with other observations.[18a, 18b] Tomonaga[18c] showed that at a water pressure below 130 m, water enters systemic organs and diatoms can be detected in these organs.

Injuries on Drowned Persons

Wounds may be found on external examination of drowned persons. Such wounds may be produced before, at the time of, or after immersion. Before immersion they may be of accidental, suicidal or homicidal origin. At the time of immersion they may be produced by the deceased striking hard objects such as rocks or stones. After immersion a body may be washed up against hard objects in the water or be attacked by fishes and crustaceans.

It is often difficult to distinguish between these types of injury. Ante-mortem wounds can only be differentiated from post-mortem wounds if the ante-mortem injury has preceded the drowning by at least one hour or longer. In such cases

histological evidence of tissue reaction may be found in the wounds. The absence of tissue reaction, however, would not exclude an ante-mortem origin for the wound (p. 211).

The Problem of determining whether a Person was Alive or Dead at the Time of Immersion

Death may occur from reflex shock or natural causes during immersion, while a body may be disposed of after death to conceal a murder. The signs of drowning will be absent in these cases, but difficulties may arise if the body has been recovered in a state of advanced putrefaction (p. 100).

Reflex shock is seen most commonly in old or debilitated subjects or in cases of immersion in very cold water. It is never possible to establish that death was due to reflex shock, but a presumption may be raised in certain circumstances if all other possibilities can be excluded.

Death from natural causes during bathing is uncommon. In these cases some lesion which could have caused death rapidly is usually demonstrable at autopsy.

Dead bodies are sometimes disposed of in the sea, rivers, or wells to conceal murder. In these cases, apart from the absence of the signs of drowning, the injury responsible for the death can usually be demonstrated, provided that putrefaction is not too far advanced. The type of problem which arises in these circumstances may be illustrated by the findings in one of our cases:

One evening a farm labourer was overheard quarrelling with his wife in a small hut which they occupied on the farm. When the farmer went to call the labourer on the following morning, he found that both the man and his wife had left with all their belongings. Ten days later the farmer noticed a grain bag floating in his dam. The bag contained the body of the woman. Her head was projecting from the open end of the bag and the rest of her body was firmly compressed in the bag. The deceased's hands and feet were wrinkled and sodden. Externally the skin was distended and green in colour. Areas of desquamation of the skin were seen over the chest, the neck and face, but no external wounds could be found. A series of vertical, parallel incisions approximately $\frac{1}{2}$ in. apart were made through the skin of the face, neck, chest and abdomen, and the underlying tissues were examined in strips. In this way several areas of reddish-brown discoloration were found in the subcutaneous tissues. These areas of discoloration were examined microscopically and found to consist of foci of blood extravasation having the appearance of bruises.

Examination of the internal organs revealed several small bruises in the intestines and a moderately extensive subarachnoid haemorrhage over the lateral surface of the left cerebrum. No fluid or frothy material was observed in the larynx, trachea or bronchi. The lungs were not distended and no haemorrhages were observed in the pleurae. On section, the lungs were a uniform dark-red colour and only a small amount of blood-stained fluid could be expressed from their cut surfaces.

Although the tissues of the body showed moderate putrefactive change, this change was not sufficiently advanced to have obscured the pathological changes ordinarily associated with drowning. The number, situation and the extent of the bruises suggested that they were probably antemortem in origin. Furthermore, the subarachnoid haemorrhage did not appear to have been caused by any disease process. On the basis of these findings it was stated that the deceased was dead at the time of her immersion and the probable cause of death was given as subarachnoid haemorrhage caused by trauma with associated injuries to other parts of the body.

The accused was arrested five months after the crime. He admitted that he had assaulted his wife, but he stated that he had not intended to kill her. When, after the assault, he found that she was dead, he became frightened, and after placing the body in a bag he disposed of it in the dam. He then left the farm. The accused was found guilty of murder with extenuating circumstances.

In certain circumstances a person may be rapidly overpowered and be thrown into water while he is alive and breathing, and under these conditions signs of drowning will be found at autopsy. It is therefore essential that all bodies that are

recovered from fluid media should be carefully examined to exclude foul play, whether the deceased has been drowned or not.

REFERENCES

1. J. Werne and I. Garrow, Sudden deaths of infants allegedly due to mechanical suffocation, *Amer. J. Publ. Hlth.*, 37 (1947) 675–687.
2. R. Turner, Personal communication, 1940.
3. W. Roughead, *The Trial of Burke and Hare*, Hodge, London, 1921.
4. T. A. Gonzales, Manual strangulation, *Arch. Path.*, 15 (1933) 55–66.
5. G. J. Romanes, *Cunninghams Textbook of Anatomy*, Oxford University Press, 1972, p. 128.

6a. B. J. Anson, *Morris' Human Anatomy*, McGraw-Hill, New York, 12th ed., 1966, p. 1414.

6b. J. A. Keen and J. Wainwright, Ossification of the thyroid, cricoid and arytenoid cartilages, *S. Afr. J. Lab. Clin. Med.*, 4 (1958) 83–108.

6c. F. E. Camps and A. C. Hunt, Pressure on the neck, *J. Forens. Med.*, 6 (1959) 129.

7. H. A. Shapiro, J. Gluckman and I. Gordon, The significance of finger nail abrasions of the skin, *Journal of Forens. Med.*, 9 (1962) 17–19.

8a. I. Prinsloo and I. Gordon, Post-mortem dissection artefacts of the neck and their differentiation from ante-mortem bruises, *S. Afr. Med. J.*, 25 (1951) 358–361.

8b. W. C. Eller and R. K. Haugen, Food asphyxiation—restaurant rescue, *New Eng. J. Med.*, 289 (1973) 81–82.

9. See also E. R. Watson, *The trial of George Joseph Smith*, Hodge, London.
10. I. Gordon, The anatomical signs in drowning. A critical evaluation, *Forens. Sc.*, 1 (1972) 389–395.
11. A. R. Moritz, Chemical methods for the determination of death by drowning, *Phys. Rev.*, 24 (1944) 70–88.
12. A. O. Gettler, A method for the determination of death by drowning, *J. Amer. Med. Ass.*, 77 (1921) 1650–1652.
13. T. G. Schwär, Drowning—its chemical diagnosis. A review, *Forens. Sci.*, 1 (1972) 411–417.
14. F. Thomas, W. Van Hecke and J. Timperman, The detection of diatoms in the bone marrow as evidence of death by drowning, *J. Forens. Med.*, 8 (1961) 142–144.
15. J. Timperman, Medico–legal problems in death by drowning, *J. Forens. Med.*, 16 (1969) 45–75.
16. J. Timperman, The diagnosis of drowning. A review, *Forens. Sci.*, 1 (1972) 397–409.
17. W. U. Spitz and V. Schneider, The significance of diatoms in the diagnosis of death by drowning, *J. Forens. Sci.*, 9 (1964) 11–18.
18. R. Nanikawa and S. Kotoku, Medico–legal observations on a dead body drawn up from the sea bed with special reference to ethanol and diatoms, *Forens. Sci.*, 3 (1974) 225–232.

18a. B. Mueller, *Gerichtlike Medizin*, Springer Verlag, Berlin, 1953.

18b. Y. Shinzawa, On the invasion of water into the dead bodies in water, *Nagasaki Med. J.*, 32 (1957) 256–270 (Japanese).

18c. T. Tomonaga, On some questions in the practice of diatom method as the evidence of drowning and on the corpse under high water pressure, *Jap. J. Leg. Med.*, 17 (1963) 188–189 (Japanese).